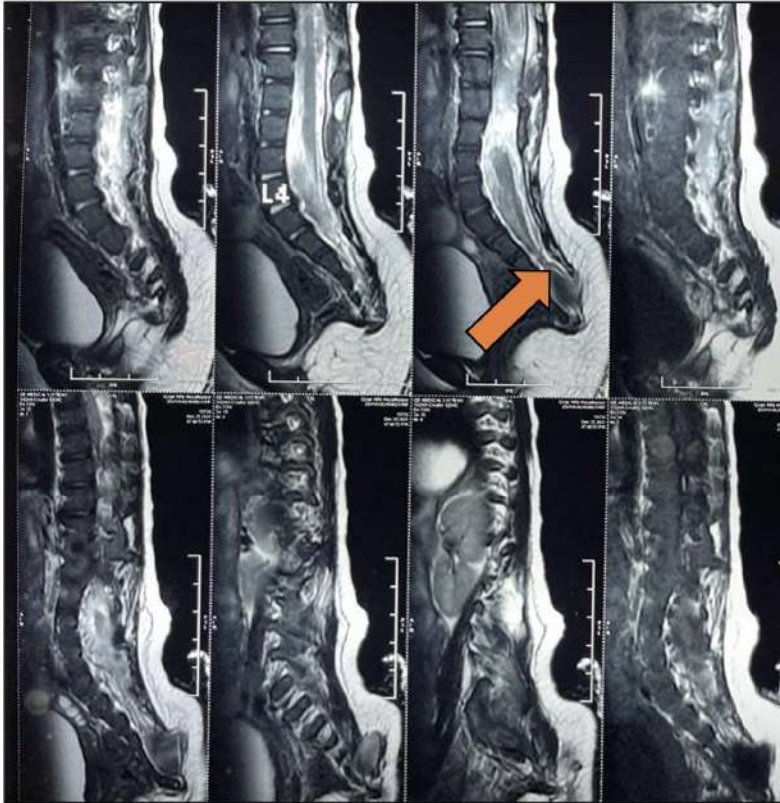
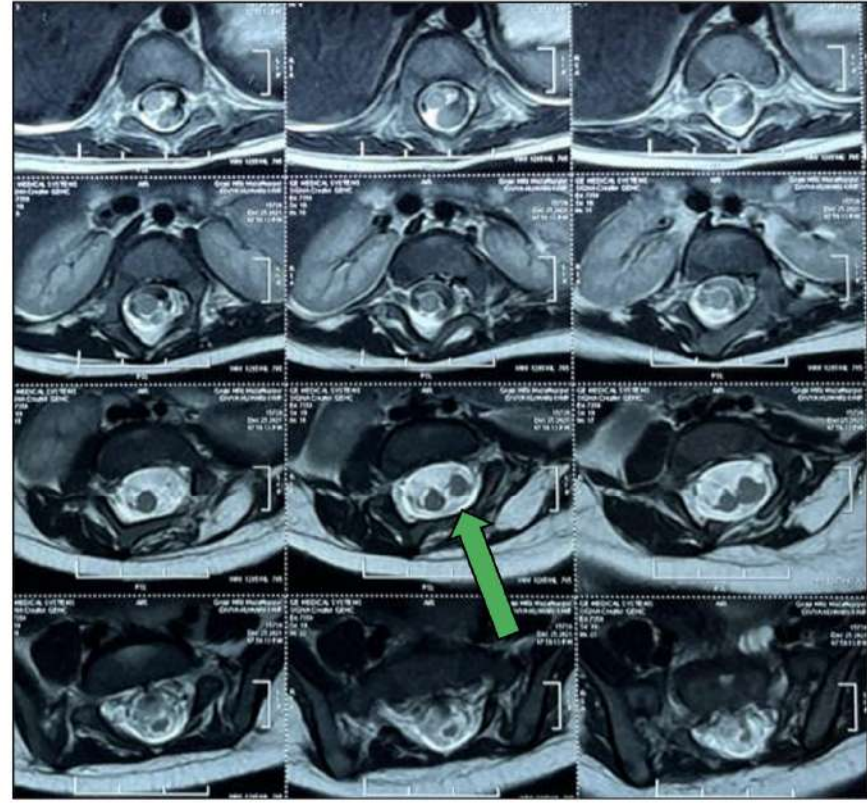


Radiology



MRI- T2WI Sagittal view
Myelocystocele at Sacral level



MRI- T2WI Axial view
Split cord malformation at T10-L3 level

- The cord is low lying and ends at L5 vertebra level
- The posterior element is deficient distal to L3 vertebra and extent up to the upper sacral vertebrae
- Splitting of the spinal cord noticed with no obvious bony septation
- Terminal cystic dilation noted, hypointense on T2WI suggestive of myelocystocele

Radiological Impression

➤ Differential Diagnosis

